

Pupillary Expansion

A valuable ally for cataract extraction in glaucoma patients.

BY ALBERT S. KHOURI, MD

Patients with coexistent cataract and glaucoma present a unique set of surgical challenges, whether or not they are undergoing a staged or combined procedure. Poor pupillary dilation is not uncommon in eyes with glaucoma and may relate to factors such as the development of posterior synechiae (from prior surgery, chronic inflammation, the long-term use of miotic medications, etc.) or iris abnormalities (intraoperative floppy iris syndrome or history of acute or chronic angle closure, presence of exfoliation or trauma, among other causes). Potential complications include failure to create a circular continuous capsulorhexis, anterior capsular tears, posterior capsular rupture, and vitreous loss. Intraoperative miosis during phacoemulsification may further limit visibility and increase the risk of complications and iris injury (“phaco bites”), which can cause increased inflammation and have long-standing effects on vision.

Surgeons must therefore use pupillary expansion techniques to achieve optimal outcomes for glaucoma patients. Although simple viscodilation may work in some eyes, iris retraction hooks and pupillary expansion rings are often necessary to stabilize the iris and maintain the optimal pupil size. This article discusses the applications of the Malyugin Ring (MicroSurgical Technology) for pupil management in glaucoma patients undergoing phacoemulsification.

ADVANTAGES

Using the Malyugin Ring in combined cataract and glaucoma surgery avoids placing additional incisions at the limbus as it is deployed through the main phaco incision. Minimizing trauma to the ocular surface is particularly important in glaucomatous eyes. Additional incisions in proximity to a filtering bleb may lead to bleb trauma, leaks, or bleb-related infections.

I also find the Malyugin Ring to be well adapted for use in patients with uveitic or traumatic glaucoma. These eyes typically have been treated with glaucoma tube shunts, and the ring enables me to avoid additional incisions close to the limbus, conjunctiva, or the scleral graft edges covering the tube.

“Postoperatively, the ring’s effect on ocular tissues is minimal, which is advantageous in glaucomatous eyes.”

VERSATILITY

The Malyugin Ring comes in two diameter sizes. Whenever possible, I use the 7-mm ring, because I find it offers excellent surgical exposure to the anterior capsule and the lens during phacoemulsification. The 6.25-mm ring is useful for eyes with a more crowded anterior segment.

The Malyugin Ring creates by design a balanced, symmetrical tension around the four scrolls, so the pupillary sphincter does not stretch in one direction more than another. With this design, trauma to the iris is not likely. Based on my experience, postoperatively, the ring’s effect on ocular tissues is minimal, which is advantageous in glaucomatous eyes, where postoperative inflammation can cause spikes in IOP, compromise filtering bleb function, and complicate the postoperative course.

SURGICAL PEARLS

The Malyugin inserter is designed to allow passage of the Malyugin Ring through a tunnelled incision. I typically use a 2.4-mm clear corneal incision, which need not stretch to accommodate the device. I achieve smooth entry of the bevel-tipped inserter into the anterior chamber by gently depressing the posterior lip of the incision as I maneuver the inserter through the wound (Figure 1).

It is important to maintain a well-formed and deep anterior chamber during the introduction of the ring inserter so as not to encroach on the anterior lens capsule with the inserter. I introduce the Malyugin Ring into the chamber with a slow, controlled movement,

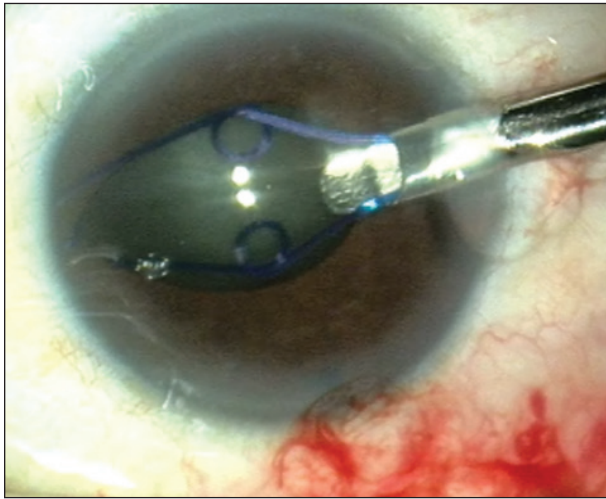


Figure 1. The Malyugin inserter allows smooth passage of the ring through a 2.4-mm clear corneal incision.

with the leading distal scroll directed slightly more posteriorly toward the anterior lens capsule to engage the pupil facing the wound. I then slowly deploy another scroll as the ring opens. Ideally, I will engage three of the four scrolls without using additional instruments. Often, however, I end up with just two of the scrolls in place holding the pupil and two scrolls above the iris. A Lester, Kuglen, Sinskey, or similar hook instrument can then be used to engage the remaining one or two scrolls (Figure 2).

After I insert the ring, I use a hook to center it for optimal capsulorhexis creation and then proceed with the cataract surgery. For the actual lens removal, I advise chopping the nucleus into small pieces or performing divide and conquer to avoid bringing up large nuclear pieces through the ring (particularly with the 6.25-mm model). A stop and chop technique may involve managing a heminuclear piece through the ring, which may lead to unnecessary encroachment on the device during phacoemulsification. One limitation of the Malyugin Ring is that it provides a predetermined area of exposure to the lens (6.25- or 7-mm diameter), which occasionally may not be sufficient. Inadvertent infringement on the device intraoperatively will also affect the entire ring (unlike iris retraction hooks for example that provide four or five independent contact points).

At the end of surgery, I disengage the scrolls from the pupillary margin. With the anterior chamber still maintained by a viscoelastic, I usually disengage one of the loops and then use a Sinskey hook to dial the Malyugin Ring out of the iris plane. I then introduce the inserter through the main corneal incision to

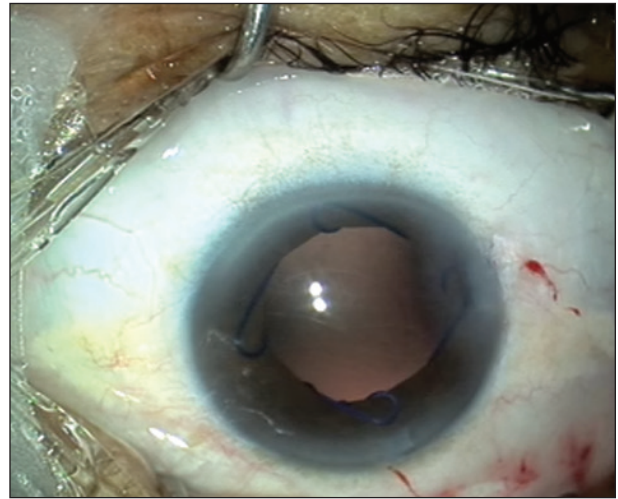


Figure 2. Once in place, the Malyugin Ring creates eight points of fixation to firmly secure the iris.

retract the ring back into the injector handpiece by pulling the inserter thumb button backward. With this technique, I can usually remove the ring smoothly from the anterior chamber in a few seconds. The Osher Modification to the Malyugin Ring Injector (MicroSurgical Technology) is designed to make the insertion, manipulation, and removal of the device easier and safer, especially in small eyes or those with shallow anterior chambers.

CONCLUSION

The Malyugin Ring is a valuable device for complex cataract surgery in glaucoma patients. I find it intuitive to work with and well suited for resident training because of its forgiving design. The learning curve is short, and trainees are usually comfortable using it after four or five procedures. Above all, the Malyugin Ring minimally disturbs the iris, and its atraumatic insertion and removal reduce the risk of postoperative inflammation that can easily negate the benefits of filtering surgery for glaucoma patients. ■

Section Editor Richard A. Lewis, MD, is in private practice in Sacramento, California. Dr. Lewis may be reached at (916) 649-1515; rlewiseyemd@icloud.com.

Albert S. Khouri, MD, is an assistant professor, program director of the Ophthalmology Residency, and associate director of the Glaucoma Division at Rutgers University-New Jersey Medical School in Newark, New Jersey.

He acknowledged no financial interest in the products or company mentioned herein. Dr. Khouri may be reached at (973) 972-2045; albert.khouri@rutgers.edu.

